

## Mapping Surface Variability of the Central Sulcus in Musicians

Shuyu Li<sup>1</sup>, Ying Han<sup>2,3</sup>, Deyi Wang<sup>3</sup>, Hong Yang<sup>4,5</sup>, Yubo Fan<sup>1</sup>, Yating Lv<sup>3</sup>, Hehan Tang<sup>4</sup>, Qiyong Gong<sup>4</sup>, Yufeng Zang<sup>3</sup> and Yong He<sup>3</sup>

<sup>1</sup>School of Biological Science and Medical Engineering, Beijing University of Aeronautics and Astronautics, Beijing, 100191 China, <sup>2</sup>Department of Neurology, Xuanwu Hospital, Capital Medical University, Beijing, 100053 China, <sup>3</sup>State Key Laboratory of Cognitive Neuroscience and Learning, Beijing Normal University, Beijing 100875, China, <sup>4</sup>Department of Radiology, Huaxi MR Research Center, West China Hospital of Sichuan University, Chengdu, 610041 China and <sup>5</sup>Department of Radiology, First Affiliated Hospital of College of Medical Science, Zhejiang University, Hangzhou, 310003 China

Shuyu Li and Ying Han contributed equally to this work.

**We employed a sulcal geometry-based approach to investigate the morphology of the central sulcus (CS) in musicians (pianists). The anterior and posterior walls of the CS were first manually outlined from high-resolution magnetic resonance (MR) images of 41 right-handed subjects (20 musicians and 21 controls), followed by a surface reconstruction and parameterization procedure to ensure the anatomical correspondence of surface locations across subjects. The intrasulcal length, surface area, and local variability of the CS were measured. There were no significant differences in either the intrasulcal length or surface area of the anterior or posterior walls between the 2 groups. However, we observed that the controls had a pronounced left-larger-than-right asymmetry that was reduced in the musicians. Importantly, we found that the musicians showed greater local variability in the middle section (i.e., somatotopic hand area) of the right CS and the lower section of the left CS as compared with the controls. Further analysis revealed significantly negative correlations between the variability of the middle section of the right CS and the age of commencement of musical training. Our findings suggest that the musicians might be associated with plastic changes in the 3D morphology of the CS in response to long-term motor skill training.**

**Keywords:** asymmetry, MRI, pianist, plasticity, primary motor cortex, primary sensory cortex, sulcal variability

Previous studies have demonstrated that both sensory stimulation and the acquisition of motor skills are accompanied by changes in functional and structural organization of the human sensorimotor areas (Pascual-Leone et al. 1993, 1995; Schlaug et al. 1994; Karni et al. 1995; Herve et al. 2005). These studies are important for understanding adaptations or plasticity in the neural circuitry of the brain. Musicians represent an ideal model to explore the plastic changes in brain structures (Munte et al. 2002) because they are skilled in performing complex motor tasks after extensive, long-term training. Several functional neuroimaging studies have shown that musicians had different patterns of neuronal activation in the primary motor and sensory cortices areas in comparison with controls (Schlaug et al. 1994; Elbert et al. 1995; Hund-Georgiadis and Von Cramon 1999; Jäncke et al. 2000; Krings et al. 2000; Schlaug 2001; Lotze et al. 2003). There has also been increasing evidence for structural changes in musicians, such as increased gray matter density or volume in the primary sensorimotor cortical areas (Schlaug 2001; Gaser and Schlaug 2003; Schlaug et al. 2005).

The central sulcus (CS), also known as the fissure of Rolando, is “a double S-shaped fissure that extends obliquely upward and backward on the lateral surface of each cerebral hemisphere of the brain and is located at the boundary between the frontal and parietal lobes” (The American Heritage Medical Dictionary 2007). The 3D anatomy of the CS includes motor and sensory maps, somatotopically organized according to Penfield’s classical “homunculus” (Penfield and Rasmussen 1950). Investigation of the 3D sulcal anatomy of the CS was thought to be crucial for revealing characteristic morphological features and matching anatomy and function (Sastre-Janer et al. 1998). Several neuroimaging studies have shown that the 3D morphology of the CS could be associated with handedness (Amunts et al. 2000), gender (Davatzikos and Bryan 2002; Cykowski et al. 2008), genetics (Goualher et al. 2000), and normal aging (Cykowski et al. 2008). However, according to our knowledge, only 2 prior studies have examined changes in the 3D morphology of the CS in musicians. In the first study, Amunts et al. (1997) analyzed the intrasulcal length of the precentral gyrus (ILPG), defined as the length of the posterior wall of the precentral gyrus bordering the CS in horizontal sections, and found that the musicians exhibited a relatively symmetrical ILPG, whereas the right-handed controls had a pronounced left-larger-than-right asymmetry, suggesting that the changes in the 3D morphology of the CS are related to musical training. In the second study, Bangert and Schlaug (2006) visually inspected the Omega Sign of the CS, an anatomical landmark of the precentral gyrus that approximately corresponds to the middle section of CS and is thought to be associated with hand/finger movement representation (Yousry et al. 1997; Boling et al. 1999). They found that the musicians had more pronounced Omega Sign expression than nonmusicians. Although these 2 studies provided a means, based on surface characterization, to explore the morphological variations at a global level, they did not investigate local and subtle changes in the CS in response to motor skills. The sulcal mapping approaches (Thompson et al. 1996; Goualher et al. 2000; Davatzikos and Bryan 2002) provide a framework for identifying local changes across the interior surface anatomy of the brain. By establishing parametric meshes of the sulcus, this kind of approach can allow us to place a coordinate frame on the sulcal surface, which would enable further shape analysis, such as the encoding of statistical properties in local anatomical variations within individual sulci. Recently, sulcal mapping-based approaches have been applied to studies of normal

populations and brain disorders (Thompson et al. 1998; Goualher et al. 2000; Davatzikos and Bryan 2002; Levitt et al. 2003; Cykowski et al. 2008).

In the current study, we aimed to employ 3D statistical analysis of sulcal mapping to investigate CS morphology in musicians. We hypothesized that the musicians would show plastic geometrical changes in the sensorimotor cortex after long-term musical training. To test this hypothesis, we first outlined the anterior and posterior walls of the CS from individual high-resolution structural magnetic resonance (MR) images, followed by a 3D surface reconstruction and parameterization. Then, we calculated the intrasulcal length, surface area, and local sulcal variability according to the parameterized surface maps. Finally, the significances of the differences in the features between the musicians and controls were statistically evaluated.

## Materials and Methods

### Subjects

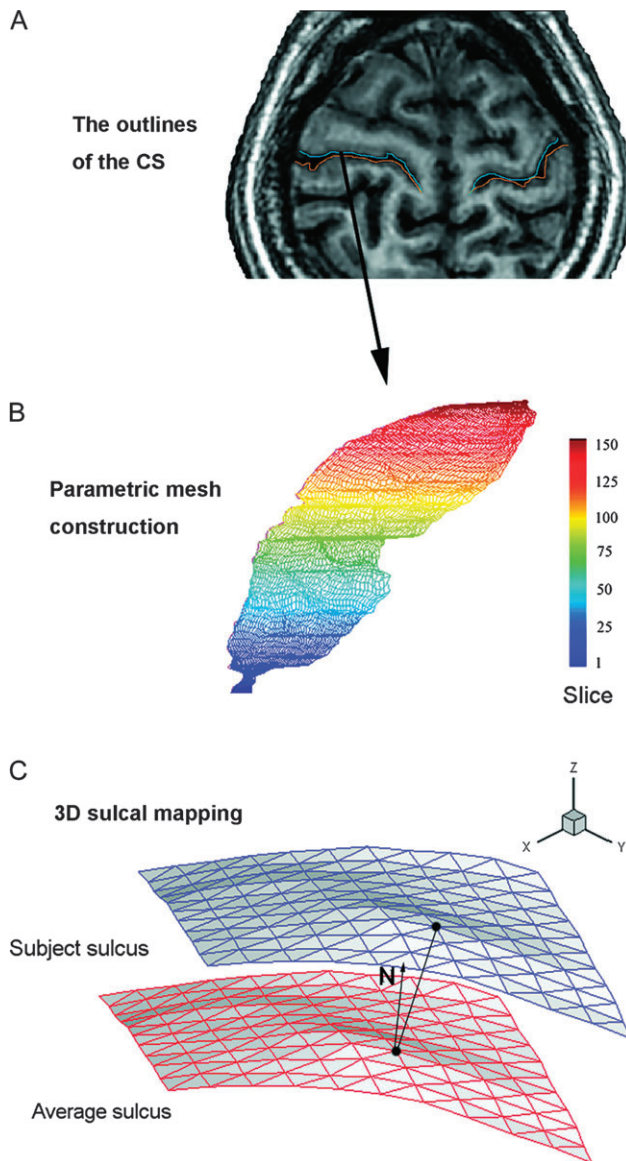
This study included 20 musicians (piano players) (12 females; age [mean  $\pm$  standard deviation]:  $22.3 \pm 2.6$  years) and 22 age- and gender-matched controls (12 females; age [mean  $\pm$  standard deviation]:  $22.4 \pm 2.6$  years) (Han et al. 2008; Lv et al. 2008). All subjects were right-handed Han Chinese people (Li 1983). The musicians were college students in music school. They began their musical training at the age of 5.5–17 ( $12.2 \pm 3.3$ ) years and had an average of  $10.4 \pm 4.2$  years of piano training by the day of magnetic resonance imaging (MRI) scanning. The control group comprised medical school students ( $n = 18$ ) and people who lived near the hospital ( $n = 4$ ). The scan of 1 control was excluded from further analysis due to imaging artifacts. None of the individuals in the control group had previously been trained to play a musical instrument or to be a professional typist. All subjects had no history of neurological, psychiatric, or movement disorders. Written informed consent was obtained from each participant. This study was approved by the Institutional Review Board of HuaXi Hospital.

### Image Acquisition

MR imaging was carried out on a 3-T MR scanner (GE EXCITE, Milwaukee, WI). High-resolution 3D T1-weighted images were axially acquired by spoiled gradient-recalled sequence: repetition time = 8.5 ms; echo time = 3.4 ms; field of view =  $240 \times 240$  mm; matrix =  $512 \times 512$ ; 156 axial slices; and thickness/gap = 1 mm/0 mm.

### Three-Dimensional Extraction of the CS

All native MR images were first spatially normalized into the Talairach space (Talairach and Tournoux 1988) using a linear transformation (<http://afni.nimh.nih.gov/afni/>). The resulting images were then treated with the MRICro software (<http://www.mricro.com>) to extract the CS. Briefly, the left and right CS were first identified, according to a prior neuroanatomical atlas (Duvernoy 1999). The boundaries of the CS (including anterior and posterior boundaries) in each section were then drawn as a line starting at the surface of the brain, outlining the posterior wall of the precentral gyrus (the anterior wall of the CS) and the anterior wall of the postcentral gyrus (the posterior wall of the CS). Figure 1A shows the outlined anterior and posterior walls of the CS in the horizontal section in 1 representative subject. To estimate the reliability of measures based on the manual outlining, the 2 raters, who were blinded for the sides (left and right) of the brain, traced both walls of the CS on 6 randomly selected brain volumes. Interrater correlation coefficients for the intrasulcal lengths of the anterior and posterior walls of the CS were 0.95 and 0.92, respectively. Mean intrarater correlation coefficients for the intrasulcal lengths of both walls were 0.96 and 0.94 for the 2 raters. Of note, there were interruptions found in the manual outlines of the CS in the image slices of 4 subjects (2 musicians and 2 controls). To ensure the integrity of the CS, we directly linked these interrupted points as a simple approximation (Supplementary Fig. 1).



**Figure 1.** A flowchart for surface construction and 3D mapping of the CS. (A) The outlines of the anterior (i.e., posterior wall of the precentral gyrus, blue lines) and posterior (i.e., anterior wall of the postcentral gyrus, yellow lines) walls of the CS. (B) Parametric mesh construction of the anterior wall of the left CS. The blue-red hue scale indicates the changes from the inferior to the superior CS. (C) Three-dimensional sulcal mapping. The red surface mesh represents the average surface from all the musicians and the blue represents the surface acquired for a single musician. The black dots represent 2 corresponding points on the 2 surfaces. The black segment between the 2 points represents a 3D displacement vector.  $N$  is the normal direction of this point on the average surface.

### Surface Reconstruction from Planar Cross-Sections

The manual outlining procedure described previously yielded a sampling of approximately 15 000 points for each wall of the CS. The 3D coordinates of these points represented the details of each sulcal surface at a local level. Taking into consideration the fact that the spatial distribution of these digitized points was not uniform across subjects, it was difficult to directly compare the morphological differences at each location of the CS between groups. To obtain the anatomical correspondences of surface locations along the outlined walls across subjects, we employed a surface mesh modeling method (Thompson et al. 1996), in which a standard surface representation was generated for each sulcus. This procedure was analogous to stretching a regular rectangular grid over all the scattered digitized points. For

a stack of sulcus outlines contoured in a series of horizontal sections, the algorithm generated a regular parametric mesh with uniformly spaced points. Briefly, we first divided each outlined cross-sectional contour into  $I$  partitions, each of which had the same arc length. Thus, the points with the same assigned indices on each cross-sectional contour constituted a curve along the lateral axis of Talairach space, which was further uniformly segmented into  $J$  partitions based on the arc length, again. The details of the mesh construction algorithm have been previously described in other works (Thompson et al. 1996, 1998). Using this approach, we constructed each CS surface as a regular parametric grid with the same size  $I \times J$ . Figure 1B shows the 3D morphology of the anterior wall of the left CS in a representative subject. Notably, the parameterization procedure used here provided a practical way to convert dense systems of points into entirely parametric surfaces that can be visualized and compared geometrically and statistically (Thompson et al. 1996).

### Surface-Based Measurements

#### Intrasulcal Length and Surface Area

We first utilized the intrasulcal length and surface area measures to represent the morphometry of the entire CS. The intrasulcal length was defined as the total number of points in each outline from all horizontal sections, similar to the ILPG measurement proposed by Amunts et al. (1997). The intrasulcal lengths of the anterior and posterior walls of the CS were then calculated. The surface area for each wall of the CS was calculated by summing the areas of all grids in the parameterized surface, where the area of a grid was defined as the sum of the areas of 2 triangles within the grid.

#### Local Variability in Sulcal Surface Meshes

In this study, we utilized a popular surface-based method (Thompson et al. 1996) to evaluate the variability of surface meshes. Briefly, for each group, an average surface representation (Fig. 1C) was first obtained by averaging the 3D position vectors of the corresponding nodes across all subjects. The nodal points were considered matched if they had the same grid locations with their respective surfaces. Local variability was then computed as the 3D displacement vector between the 2 corresponding points derived from the individual surface and the average surface of this group, thus yielding a displacement map in the stereotaxic space. For a complete mathematical description, see Thompson et al. (1996). Notably, the local variability of surface meshes can also be assessed by using a nonlinear registration procedure, but this incurs a high computation cost (Christensen et al. 1996).

To further explore the directional trends of local variability, the measure of 3D spatial variability of each point on the sulcal surface was decomposed into the component along the normal direction of the corresponding point of the average surface mesh. This normal component was defined as the projection of the displacement between each vertex in each subject and the corresponding vertex in the average surface mesh for this group to the unit normal of this vertex in the average mesh. We calculated the normal component  $f_{ij}$  of 3D spatial variability of the  $j$ th vertex in the  $i$ th subject as (Yushkevich et al. 2003):

$$f_{ij} = \frac{\sum_{k \in N(j)} (x_{ij} - \bar{x}_j)^T N_j \Delta A_k}{\sum_{k \in N(j)} \Delta A_k}, \quad (1)$$

where  $N(j)$  is the 4-neighbor mesh grid of the  $j$ th vertex,  $\bar{x}_j$  and  $N_j$  are the position vector and approximate unit normal of the  $j$ th vertex in the average surface, and  $\Delta A_k$  is the area element, computed as the area of each mesh that was adjacent to the  $j$ th vertex in the average surface. If this measure has a positive value, it indicates that the individual surface mesh has outward deformation with respect to the average surface mesh and vice versa.

#### Asymmetry Score

In this study, we also calculated the asymmetry of the global and local measures of the CS. An asymmetry score was obtained for each measure according to  $(R - L) / [0.5 \times (R + L)]$ , where  $R$  and  $L$  are the measurements of the right and left hemispheres, respectively. Negative

values indicate leftward asymmetry, whereas positive values indicate rightward asymmetry.

### Statistical Analysis

#### Global

To determine whether there were significant differences in the values of each global measure (intrasulcal length, surface area, and mean surface variability), a 2-way repeated-measures analysis of variance (ANOVA) with group (musicians and controls) as a between-subject factor and side (left and right) as a repeated-measures factor was performed. The asymmetry scores of each measure were subject to a 2-sample  $t$ -test to assess the between-group differences. The asymmetry scores within each group were also analyzed using a 1-sample  $t$ -test to determine whether they were significantly different from 0. Furthermore, we calculated Pearson's correlation coefficients between each global measure and the age of commencement of musical training.

#### Local

To determine whether there were significant between-group differences in locally specific morphology, 2-tailed 2-sample  $t$ -tests were performed on local variability in a vertex-by-vertex manner. We also calculated Pearson's correlation coefficient between the local variability of each vertex and the age of commencement of musical training. The results would be considered significant if  $P < 0.05$  (uncorrected).

### Results

#### Intrasulcal Length and Surface Area of the Anterior and Posterior Walls of the CS

Table 1 presents the values for intrasulcal length and surface area of the anterior and posterior walls of the CS. "Intrasulcal Length": A 2-way repeated-measure ANOVA for the intrasulcal length in the anterior walls of the CS showed no effect of group ( $F_{1,39} = 0.005$ ; nonsignificant [NS]) but a significant effect of side ( $F_{1,39} = 5.81$ ,  $P = 0.021$ ) with no interaction between the 2 factors ( $F_{1,39} = 1.26$ ), NS. The results in the posterior walls of the CS were similar to those found in the anterior walls ( $F_{1,39}[\text{group}] = 0.30$ , NS;  $F_{1,39}[\text{side}] = 17.17$ ,  $P = 0.0002$ ;  $F_{1,39}[\text{group-by-side}] = 0.98$ , NS). "Surface Area": A 2-way repeated-measure ANOVA showed no significant effects for the surface area in the anterior walls of the CS ( $F_{1,39}[\text{group}] = 0.001$ , NS;  $F_{1,39}[\text{side}] = 2.15$ , NS;  $F_{1,39}[\text{group-by-side}] = 0.62$ , NS). A 2-way repeated-measure ANOVA for the surface area in the posterior walls of the CS showed no effect of group ( $F_{1,39} = 0.08$ , NS) but a significant effect of side ( $F_{1,39} = 8.93$ ,  $P = 0.005$ ) with no interaction between the 2 factors ( $F_{1,39} = 0.51$ , NS).

**Table 1**

Intrasulcal length and surface area of the anterior and posterior walls of the CS

	Musicians	Controls
Anterior walls of the CS		
Intrasulcal length ( $\times 10^3$ mm)		
Left	4.83 $\pm$ 0.56	4.89 $\pm$ 0.43
Right	4.77 $\pm$ 0.38	4.72 $\pm$ 0.31
Surface area ( $\times 10^3$ mm <sup>2</sup> )		
Left	2.51 $\pm$ 0.36	2.53 $\pm$ 0.21
Right	2.49 $\pm$ 0.22	2.47 $\pm$ 0.16
Posterior walls of the CS		
Intrasulcal length ( $\times 10^3$ mm)		
Left	4.61 $\pm$ 0.42	4.71 $\pm$ 0.31
Right	4.46 $\pm$ 0.36	4.47 $\pm$ 0.35
Surface area ( $\times 10^3$ mm <sup>2</sup> )		
Left	2.41 $\pm$ 0.32	2.46 $\pm$ 0.20
Right	2.33 $\pm$ 0.22	2.32 $\pm$ 0.22



**Table 2**

Asymmetry indices of intrasulcal length and surface area of the anterior and posterior walls of the CS

	Musicians	Controls	<i>P</i> value
Anterior walls of the CS			
Intrasulcal length	-0.01 ± 0.07 ( <i>P</i> = 0.564)	-0.03 ± 0.05 ( <i>P</i> = 0.008)*	0.223
Surface area	-0.002 ± 0.09 ( <i>P</i> = 0.912)	-0.03 ± 0.06 ( <i>P</i> = 0.063)	0.325
Posterior walls of the CS			
Intrasulcal length	-0.03 ± 0.06 ( <i>P</i> = 0.024) *	-0.05 ± 0.07 ( <i>P</i> = 0.004)*	0.308
Surface area	-0.03 ± 0.10 ( <i>P</i> = 0.176)	-0.06 ± 0.09 ( <i>P</i> = 0.013)*	0.395

Note: The italic fonts represent the *P* values from 1-sample *t*-tests (asymmetry scores vs. zero; \**P* < 0.05). The last column indicates the *P* values from 2-sample *t*-tests for between-group differences in the asymmetry scores.

Table 2 presents the asymmetry indices of intrasulcal length and surface area of the anterior and posterior walls of the CS. “Intrasulcal Length”: The controls showed a significant leftward asymmetry in both the walls of the CS (anterior:  $t[20] = -2.97$ , *P* = 0.008; posterior:  $t[20] = -3.30$ , *P* = 0.004; 1-sample *t*-tests). In the musician group, there was significant leftward asymmetry in the posterior walls but not in the anterior walls of the CS (anterior:  $t[19] = -0.59$ , NS; posterior:  $t[19] = -2.46$ , *P* = 0.024; 1-sample *t*-tests). “Surface Area”: The controls showed significant leftward asymmetry or a trend toward leftward asymmetry in both walls of the CS (anterior:  $t[20] = -1.97$ , *P* = 0.063; posterior:  $t[20] = -2.72$ , *P* = 0.013; 1-sample *t*-tests). In the musician group, there was no significant asymmetry in both walls of the CS (anterior:  $t[19] = -0.11$ , NS; posterior:  $t[19] = -1.41$ , NS; 1-sample *t*-tests). Taken together, the data indicate that the controls had pronounced leftward asymmetry in both the intrasulcal length and surface area of the anterior or posterior walls of the CS, but this asymmetry was obviously reduced in the musicians. Further statistical analysis revealed no significant between-group differences in these asymmetry indices (all *P* > 0.20, 2-sample *t*-tests; Table 2).

### Mean Surface Variability of the Anterior and Posterior Walls of the CS

#### Mean Surface Variability

Table 3 presents the values for mean surface variability of the anterior and posterior walls of the CS. A 2-way repeated-measures ANOVA for the mean surface variability in the anterior walls of the CS showed an effect of group ( $F_{1,39} = 5.93$ , *P* = 0.020) and side ( $F_{1,39} = 11.90$ , *P* = 0.001) without interaction between the factors ( $F_{1,39} = 0.79$ , NS). The results for the posterior walls of the CS were similar to those found for the anterior walls ( $F_{1,39}[\text{group}] = 6.19$ , *P* = 0.017;  $F_{1,39}[\text{side}] = 14.47$ , *P* = 0.0005;  $F_{1,39}[\text{group-by-side}] = 1.19$ , NS).

Table 4 presents the asymmetry indices of mean surface variability of the anterior and posterior walls of the CS. In the controls, there was a leftward asymmetry in the anterior walls of the CS but not in the posterior walls (anterior:  $t[20] = -2.31$ , *P* = 0.032; posterior:  $t[20] = -1.63$ , NS; 1-sample *t*-tests). In the musicians, there was a significant leftward asymmetry in both walls (anterior:  $t[19] = -3.48$ , *P* = 0.003; posterior:  $t[19] = -3.23$ , *P* = 0.004; 1-sample *t*-tests). There were no significant differences found in the asymmetry indices between the 2 groups (all *P* > 0.40, 2-sample *t*-tests; Table 4).

**Table 3**

Mean surface variability of the anterior and posterior walls of the CS

	Musicians	Controls
Anterior walls of the CS		
Mean local variability (mm)		
Left	1.66 ± 0.66	1.27 ± 0.66
Right	1.17 ± 0.38	0.97 ± 0.34
Posterior walls of the CS		
Mean local variability (mm)		
Left	1.71 ± 0.74	1.27 ± 0.58
Right	1.21 ± 0.44	0.98 ± 0.32

**Table 4**

Asymmetry indices of mean surface variability of the anterior and posterior walls of the CS

	Musicians	Controls	<i>P</i> value
Anterior walls of the CS			
Mean sulcal variability	-0.32 ± 0.41 ( <i>P</i> = 0.003) *	-0.22 ± 0.44 ( <i>P</i> = 0.032) *	0.470
Posterior walls of the CS			
Mean sulcal variability	-0.31 ± 0.42 ( <i>P</i> = 0.004)*	-0.19 ± 0.54 ( <i>P</i> = 0.120)	0.461

Note: The italic fonts represent the *P* values from 1-sample *t*-tests (asymmetry scores vs. zero; \**P* < 0.05). The last column indicates the *P* values from 2-sample *t*-tests for between-group differences in the asymmetry scores.

### Vertex-Based Local Variability in the Anterior and Posterior Walls of the CS

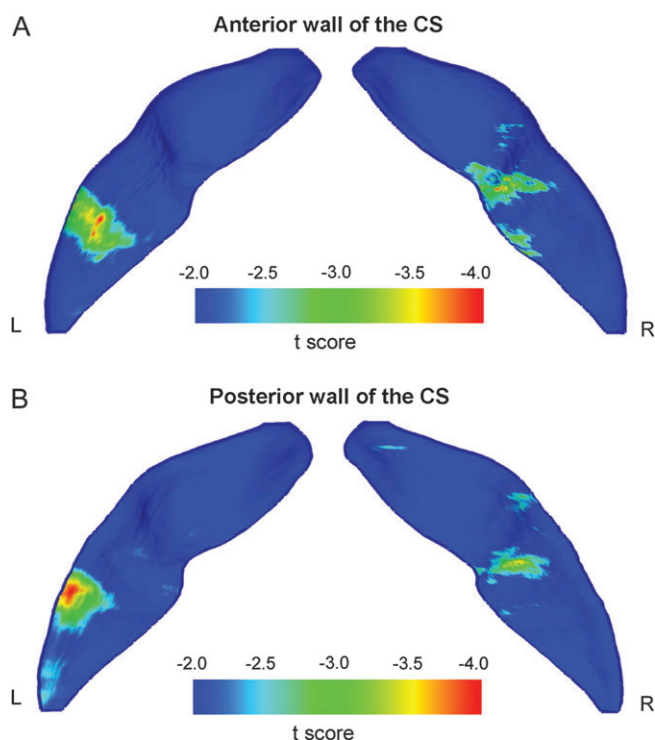
We next examined between-group differences in local variability of each vertex through the 2 walls of the CS. We found that the musicians showed significantly (*P* < 0.05) greater local variability in the middle section of the anterior walls of the right CS and the lower section of the left CS as compared with the controls (Fig. 2A and Supplementary Video 1). The changing patterns of the posterior walls of the CS were similar to those found in the anterior walls (Fig. 2B and Supplementary Video 2).

### Relationship between the CS Measures and Age of Commencement of Musical Training

In the musician group, there were no significant correlations between the global measures (intrasulcal length, surface area, and mean local variability) of the CS and the age of commencement of musical training. There were also no significant correlations found between the local variability of the left CS and the age of commencement. However, we noted that, in the right CS, the local variability of the middle section of both walls showed significantly (*P* < 0.05) negative correlations with the age of commencement of musical training (anterior: Fig. 3A and Supplementary Video 4; posterior: Fig. 3B and Supplementary Video 5).

### Discussion

In this study, we employed a sulcal geometry-based approach to investigate the plastic changes in the 3D morphology of the CS in musicians. The morphological measures including the global intrasulcal length, surface area, and local surface variability were computed based on reconstructed surface meshes. Compared with the controls, the musicians had no significant changes in either intrasulcal length or surface area in the CS. However, we found that the musicians showed significantly greater local variability in the middle section of both walls of the right CS, and these changes were associated with the age of commencement



**Figure 2.** Statistical differences of local sulcal variability between the musicians and controls. Compared with the controls, the musicians showed significantly ( $|t| > 2.0$ ,  $P < 0.05$ ) greater local variability in the middle section (i.e., somatotopic hand area) of the right CS and the lower section of the left CS. The results were overlapped onto the mean CS surface that was obtained by averaging the position vector of the anterior or posterior walls of the CS from all the subjects. The surfaces in the figures are shown from the posterior view. L, left hemisphere; R, right hemisphere. (A) The anterior wall of the CS. (B) The posterior wall of the CS. Also see Supplementary Videos 1 and 2 for the results in the anterior and posterior walls of the CS, respectively. For individual 3D maps of the CS from one representative musicians and controls, see Supplementary Video 3A,B.

of musical training. Together, our results provide evidence for the plasticity of structural morphology of the CS in musicians after long-term motor skill training.

### ***Morphometric Differences in the CS between the Musicians and the Controls***

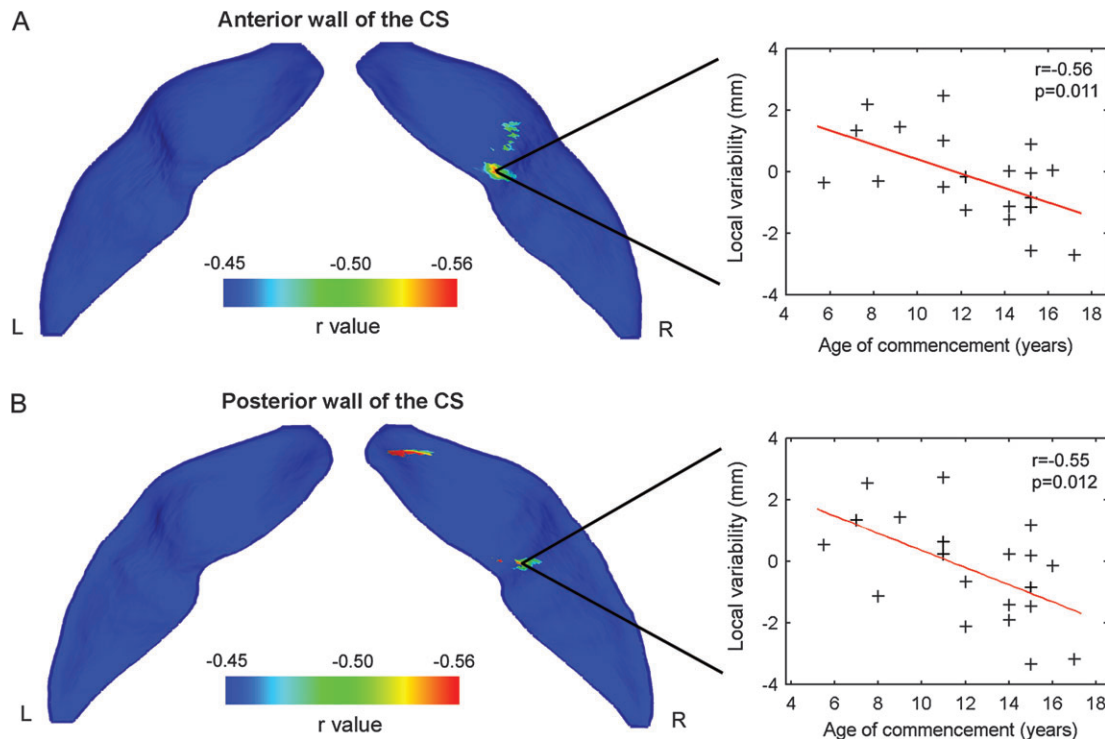
#### ***Intrasulcal Length and Surface Area.***

We found that there were no significant differences in either the intrasulcal length or the surface area of the anterior or posterior walls of the CS between the musicians and the controls. However, the right-handed controls showed prominent leftward asymmetry in the 2 global measures, but this asymmetry was obviously diminished in the musicians (Table 2). Several previous studies have examined the anatomical asymmetry of the CS in right-handed subjects, but the findings are still a point of controversy. For instance, White et al. (1997b) employed quantitative histological and imaging techniques to evaluate the lateral asymmetry in the depths of the human CS; they found that preferred use of the right hand occurred without a gross lateral asymmetry of the primary sensorimotor system. However, using a parametric ribbon approach, Davatzikos and Bryan (2002) observed that the CS was deeper and larger in the right (nondominant) hemisphere than in the left (dominant) hemisphere. Nonetheless, Amunts

et al. (1997) found that the right-handed subjects had a leftward asymmetry in the ILPG of the CS; this asymmetry was decreased in musicians as compared with controls. Using a sulcal-based morphometry approach, Mangin et al. (2004) also found that the CS was larger in the dominant hemisphere of the human brain. The findings of Amunts et al. (1997) and Mangin et al. (2004) were in line with our study. Evidence from animal (rat) experiments has suggested that the asymmetric use of only 1 forelimb in the postweaning period can induce a larger neuropil volume and a lower cell packing density in the contralateral “forelimb” motor cortex (Diaz et al. 1994). Based on these observations, one could therefore speculate that the more symmetric anatomical morphology of the CS in the musicians shown in the present study might be associated with the pronounced proficiency of the left hand that is controlled by the right (nondominant) hemisphere.

#### ***Local Variability***

Using a sulcal geometry-based analysis, we demonstrated that the musicians had greater mean surface variability in both walls of the CS as compared with the controls (Table 3). Thompson et al. (1996) suggested that the variability in the surface geometry of the CS was the product of an almost infinite variety of evolutionary, developmental, and experiential processes. Thus, our findings of larger surface variations in both walls of the CS in musicians might be associated with long-term training and motor skill learning. Furthermore, we found that the middle section of the right CS exhibited significant differences in local variability between the musicians and the controls. Many studies have suggested that the middle section of the CS is mainly composed of the somatotopic hand area (White et al. 1997a; Yousry et al. 1997; Sastre-Janer et al. 1998; Boling et al. 1999). Functional neuroimaging studies have suggested that this region showed neuronal activation during hand motor tasks (Yousry et al. 1997; Sastre-Janer et al. 1998; Boling et al. 1999). Specifically, Gaser and Schlaug (2003) found that, compared with amateur pianists, professional pianists had increased gray matter volume in the hand area of the CS; this difference was even greater when musicians were contrasted with nonmusician controls. Thus, our findings are compatible with the results of previous studies. The plastic changes in the 3D morphology could be attributable to variations in microstructure, such as increased number of synapses and glial cells per neuron (Black et al. 1990; Isaacs et al. 1992; Anderson et al. 1994). In this study, we also noticed that the changes in the local variability of the hand area of the right CS were negatively correlated with the age of commencement of musical training, suggesting that the earlier the training, the larger the structural adaptations of the brain structure. The changes could be attributable to more skillful use of the nondominant (left) hand in the musicians as compared with the controls. It is notable that a previous study from Bangert and Schlaug (2006) also showed prominent changes in the hand area of the CS in musicians (pianists) by visually inspecting the Omega expression (a gross anatomical landmark of the precentral gyrus). However, they observed that the changes were mainly located in the dominant (left) hemisphere, a finding that is inconsistent with our study. The discrepancies could be due to different analytical methods and populations used in the 2 studies. In the present investigation, we also observed that the musicians showed greater local variability in the lower section of the left CS. To date, however, there have been few studies reporting on



**Figure 3.** The correlation between local variability and age of commencement of musical training. The focal regions with significant negative correlations ( $r < -0.45$ ,  $P < 0.05$ ) were mapped on the average surface of the CS. No significant positive correlations were found. Notably, we first defined the regions showing significant differences in local variability between 2 groups as a mask and then computed Pearson's correlation coefficients between the local variability in each vertex within the mask and age of commencement. The plots in the right column show the correlation between age of commencement of musical training and local variability of the peak vertex in the hand region of the CS. L, left hemisphere; R, right hemisphere. (A) The anterior wall of the CS. (B) The posterior wall of the CS. Also see Supplementary Videos 4 and 5 for results in the anterior and posterior walls of the CS, respectively.

the training-related changes in the brain structure. Using functional MRI, Fesl et al. (2003) demonstrated that the inferolateral segment of the CS was mainly associated with the primary motor/sensory tongue area. The relationship between the lower section of the CS and musical training still needs to be further studied in the future.

It needs to be noted that the musicians had similar changing patterns of local variability between the anterior and posterior walls of the CS. The anterior walls of the CS are associated with the primary motor cortex, and the posterior walls are associated with the primary sensory cortex. It is well known that pianists generally need precise sensory-motor coordination while performing musical tasks. We therefore speculate that the similar changes in the 2 brain structures could appear in a coordinated manner. Nonetheless, there have been very few reports on the structural and functional changes in the posterior walls of the CS in musicians. Gaser and Schlaug (2003) found that professional pianists had larger gray matter volume in the primary sensory area as compared with amateur pianists. Using magnetoencephalography, Elbert et al. (1995) showed that the fingers of the left hand of violinists had stronger representation by means of signal amplitude in the primary sensory cortex than those of a control group. Lotze et al. (2003) found that, compared with amateur violinists, professional violinists exhibited more functional activation in the primary sensory cortices. Here, we provided the evidence that the musicians had associations with the 3D morphological changes in the posterior walls of the CS in response to long-term musical training. Taken together, the present study

demonstrated that the musicians had geometric changes in the 3D morphology of both the anterior and posterior walls of the CS. These changes could reflect structural and/or functional reorganization of the sensorimotor cortex following sensory stimulation or the acquisition of new motor skills.

#### **Sulcal Mapping Approaches**

To map the changes in surface variability in the musicians, sulcal extraction was the first step to be conducted. In the present study, we manually outlined the contours of the CS, as shown in previous studies (Amunts et al. 1997; Sastre-Janer et al. 1998; Davatzikos and Bryan 2002). However, this process was time consuming and investigator dependent. Several researchers have suggested that the sulcus of the human brain can be extracted automatically through computational approaches. For instance, Goualher et al. (2000) extracted the median surface of the CS by using the Active Ribbon method. Mangin et al. (1995, 2004) developed an observer-independent sulcal extraction and recognition algorithm, achieving a correct recognition rate greater than 96% for the CS. In the future, it would be interesting to apply the automated sulcus reconstruction method to the morphometric analysis of the CS in musicians.

The sulcal mapping method used in this study included surface reconstruction, surface parameterization, and local anatomical variability analysis, as described by Thompson et al. (1996). This method has been found to be capable of characterizing variations in sulcal geometry and was recently applied to cortical sulcal analysis in brain disorders such as



Alzheimer's disease (Thompson et al. 1998) and autism (Levitt et al. 2003). Notably, these studies showed that there were directional trends of the 3D spatial variability of a sulcus along the 3 orthogonal axes of the stereotaxic space and that the variability in position was not isotropic. However, several other studies (Pizer et al. 1999; Yushkevich et al. 2003; Styner et al. 2004), including 1 of ours (Li et al. 2007), have also suggested that variations in object geometric shape can be characterized along the normal direction. By using the components along the normal direction of the mean shape, in this study, we found significant differences in the 3D morphology of the CS between the musicians and the controls. However, there were no significant differences found when we employed the measures of the 3D displacement and its 3 components along each orthogonal axis. Thus, we suspected that the changes in local variability of the CS in musicians could appear along the normal direction of each vertex in response to long-term musical training.

### **Future Considerations**

Several issues need to be further addressed. First, the musicians in this study had a wide range of age of commencement of musical training (an average age of 12.2 years [range 5.5-17]). The wide age range can allow us to explore the relation between the morphology of the CS and the age of commencement of musical training. However, Hallett (1995) suggested that the most pronounced plasticity effects could occur during the first years of life and that the plasticity could tend to decrease with increasing age. Watanabe et al. (2007) found that there might be a sensitive period (<7 years) in childhood where enriched motor training through musical practice results in long-lasting benefits for performance later in life. Thus, it would be also interesting to explore the changes in the 3D morphology of CS in musicians with an early age of commencement of musical training (e.g., <7 years old). We expect that an early musical training started in childhood could lead to a large effect size of training-induced plasticity. Second, in this study, we only correlated the changes in local variability of the CS with the age of commencement of musical training. It would also be helpful for understanding the effect of training on brain morphology if the surface variability of CS could be correlated with the intensity of training (e.g., the "cumulative life time practice") (Ericsson et al. 1993). However, in this study, we did not collect information on the intensity of musical training. We hope that in future studies this information can be collected to further address the relationship between changes in brain morphology and musical training. Third, we reported an uncorrected result in musician-related changes in local variability (Figs. 2 and 3). To correct the multiple comparisons, we performed a false discovery rate procedure at a  $q$  value of 0.05 (Genovese et al. 2002). Using this procedure, we observed that there were still significant differences in local variability of the posterior wall of the left CS between the musicians and controls (456 vertices around the red areas in the left panel of Fig. 2B). However, there were no significant differences or correlations found in the other results of local variability after the correction. Therefore, our results could be mainly considered exploratory in nature. Further studies can be implemented to explore the plastic changes in the 3D morphology of the CS by increasing the sample size to enhance statistical power, or by performing a region of interest analysis in the hand area. Finally, the present

study used cross-sectional data to investigate the relationship between specialized skills and the morphology of the CS. Therefore, we cannot exclude the possibility that these morphometric differences observed in the CS between musicians and controls might be innate. However, many histological studies in animals (Anderson et al. 1994, 2002; Kleim et al. 1996) have provided direct evidence that microstructural changes (including increased number of synapses per neuron, glial cells, and capillary density) of the primary motor cortex are related to motor skill learning and continuous motor activity. Neuro-imaging studies in humans (Amunts et al. 1997; Gaser and Schlaug 2003) have also demonstrated the association between morphology of the primary motor cortex and musician status. In the present study, we also found that the 3D morphology of the hand area of the CS showed not only significant between-group differences but also associations with the age of commencement of musical training. Thus, we speculate that our findings on the morphometric differences of the CS between the 2 groups are likely to represent the effects of the long-term motor training rather than innate predisposition. In the future, longitudinal studies must be conducted to further investigate the structural plasticity in response to long-term musical training.

### **Conclusion**

In this study, we employed a sulcal geometry-based statistical analysis approach to investigate the morphology of the CS in musicians. The major advantage of this sulcal mapping method was that it was capable of capturing subtle structural adaptations in the morphology of the CS in musicians compared with controls. Using this approach, we demonstrated that the musicians had significant changes in the 3D structure of the somatotopic hand area of the right CS; these changes were associated with the age of commencement of musical training. Our results strongly suggest that musician status is associated with plastic changes in geometric morphology of the CS, thus providing insight into the structural reorganization in musicians in response to long-term motor skill training.

### **Supplementary Material**

Supplementary Figures 1 and 2 and Videos 1-5 can be found at <http://www.cercor.oxfordjournals.org/>.

### **Funding**

Natural Science Foundation of China (grant nos. 30700182, 30870667, 30470575, 30625024, 30530290, and 30621130074); the Scientific Research Foundation for the Returned Overseas Chinese Scholars (State Education Ministry, Y.H.); the National Basic Research Program (973 program no.: 2007CB512305); National High Technology Program of China (863 program no.: 2008AA02Z408).

### **Notes**

We would like to thank American Journal Experts (<http://www.journalexperts.com/>) and Gusphyl Justin for their English editing and proofreading. *Conflict of Interest:* None declared.

Address correspondence to email: [yong.he@bnu.edu.cn](mailto:yong.he@bnu.edu.cn).

### **References**

The American heritage medical dictionary. 2007. Boston (MA): Houghton Mifflin Co.

- Amunts K, Jäncke L, Mohlberg H, Steinmetz H, Zilles K. 2000. Interhemispheric asymmetry of the human motor cortex related to handedness and gender. *Neuropsychologia*. 38:304-312.
- Amunts K, Schlaug G, Jäncke L, Steinmetz H, Schleicher A, Dabringhaus A, Zilles K. 1997. Motor cortex and hand motor skills: structural compliance in the human brain. *Hum Brain Mapp*. 5:206-215.
- Anderson BJ, Eckburg PB, Relucio KI. 2002. Alterations in the thickness of motor cortical subregions after motor-skill learning and exercise. *Learn Mem*. 9:1-9.
- Anderson BJ, Li X, Alcantara AA, Isaacs KR, Black JE, Greenough WT. 1994. Glial hypertrophy is associated with synaptogenesis following motor-skill learning, but not with angiogenesis following exercise. *Glia*. 11:73-80.
- Bangert M, Schlaug G. 2006. Specialization of the specialized in features of external human brain morphology. *Eur J Neurosci*. 24:1832-1834.
- Black JE, Isaacs KR, Anderson BJ, Alcantara AA, Greenough WT. 1990. Learning causes synaptogenesis, whereas motor activity causes angiogenesis, in cerebellar cortex of adult rats. *Proc Natl Acad Sci USA*. 87:5568-5572.
- Boling W, Olivier A, Bittar RG, Reutens D. 1999. Localization of hand motor activation in Broca's pli de passage moyen. *J Neurosurg*. 91:903-910.
- Christensen GE, Rabbitt RD, Miller MI. 1996. Deformable templates using large deformation kinematics. *IEEE Trans Image Proc*. 5:1435-1447.
- Cykowski MD, Coulon O, Kochunov PV, Amunts K, Lancaster JL, Laird AR, Glahn DC, Fox PT. 2008. The central sulcus: an observer-independent characterization of sulcal landmarks and depth asymmetry. *Cereb Cortex*. 18:1999-2009.
- Davatzikos C, Bryan RN. 2002. Morphometric analysis of cortical sulci using parametric ribbons: a study of the central sulcus. *J Comput Assist Tomogr*. 26:298-307.
- Diaz E, Pinto-Hamuy T, Fernandez V. 1994. Interhemispheric structural asymmetry induced by a lateralized reaching task in the rat motor cortex. *Eur J Neurosci*. 6:1235-1238.
- Duvernoy HM. 1999. The human brain: surface, blood supply, and three-dimensional sectional anatomy. 2nd ed. Wien: Springer.
- Elbert T, Pantev C, Wienbruch C, Rockstroh B, Taub E. 1995. Increased cortical representation of the fingers of the left hand in string players. *Science*. 270:305-307.
- Ericsson KA, Krampe RTh, Tesch-Römer C. 1993. The role of deliberate practice in the acquisition of expert performance. *Psychol Rev*. 100:363-406.
- Fesl G, Moriggl B, Schmid UD, Naidich TP, Herholz K, Yousry TA. 2003. Inferior central sulcus: variations of anatomy and function on the example of the motor tongue area. *Neuroimage*. 20:601-610.
- Gaser C, Schlaug G. 2003. Brain structures differ between musicians and non-musicians. *J Neurosci*. 23:9240-9245.
- Genovese CR, Lazar NA, Nichols T. 2002. Thresholding of statistical maps in functional neuroimaging using the false discovery rate. *Neuroimage*. 15:870-878.
- Goualher GL, Argenti AM, Duyme M, Baare WFC, Hulshoff Pol HE, Boomsma DI, Zouaoui A, Barillot C, Evans AC. 2000. Statistical sulcal shape comparisons: application to the detection of genetic encoding of the central sulcus shape. *Neuroimage*. 11:564-574.
- Hallett M. 1995. The plastic brain. *Ann Neurol*. 38:4-5.
- Han Y, Yang H, Lv YT, Zhu CZ, He Y, Tang HH, Gong QY, Luo YJ, Zang YF, Dong Q. 2008. Gray matter density and white matter integrity in pianists' brain: a combined structural and diffusion tensor MRI study. *Neurosci Lett*. Forthcoming.
- Herve P, Mazoyer B, Crivello F, Percey G, Taourio-Mazoyer N. 2005. Finger tapping, handedness and grey matter amount in the Rolando's genu area. *Neuroimage*. 25:1133-1145.
- Hund-Georgiadis M, Von Cramon DY. 1999. Motor-learning-related changes in piano players and nonmusicians revealed by functional magnetic resonance signals. *Exp Brain Res*. 125:417-425.
- Isaacs KR, Anderson BJ, Alcantara AA, Black JE, Greenough WT. 1992. Exercise and the brain: angiogenesis in the adult rat cerebellum after vigorous physical activity and motor skill learning. *J Cereb Blood Flow Metab*. 12:110-119.
- Jäncke L, Shah NJ, Peters M. 2000. Cortical activations in primary and secondary motor areas for complex bimanual movements in professional pianists. *Cogn Brain Res*. 10:177-183.
- Karni A, Meyer G, Jezard P, Adams MM, Turner R, Ungerleider LG. 1995. Functional MRI evidence for adult motor cortex plasticity during motor skill learning. *Nature*. 377:155-158.
- Kleim JA, Lussnig E, Schwarz ER, Comery TA, Greenough WT. 1996. Synaptogenesis and Fos expression in the motor cortex of the adult rat after motor skill learning. *J Neurosci*. 16:4529-4535.
- Krings T, Topper R, Foltys H, Erberich S, Sparing R, Willmes K, Thron A. 2000. Cortical activation patterns during complex motor tasks in piano players and control subjects. A functional magnetic resonance imaging study. *Neurosci Lett*. 278:189-193.
- Levitt JG, Blanton RE, Smalley S, Thompson PM, Guthrie D, McCracken JT, Sadoun T, Heinichen L, Toga AW. 2003. Cortical sulcal maps in autism. *Cereb Cortex*. 13:728-735.
- Li SY, Shi F, Pu F, Li XB, Jiang TZ, Xie S, Wang YH. 2007. Hippocampal shape analysis of Alzheimer disease based on machine learning methods. *Am J Neuroradiol*. 28:1339-1345.
- Li XT. 1983. The distribution of left and right handedness in Chinese people. *Acta Psychol Sin*. 3:268-276.
- Lotze M, Scheler G, Tan HR, Braun C, Birbaumer N. 2003. The musician's brain: functional imaging of amateurs and professionals during performance and imagery. *Neuroimage*. 20:1817-1829.
- Lv YT, Yang H, Wang DY, Li SY, Han Y, Zhu CZ, He Y, Tang HH, Gong QY, Zang YF. 2008. Correlations in spontaneous activity and gray matter density between left and right sensorimotor areas of pianist. *Neuroreport*. 19:631-634.
- Mangin JF, Frouin V, Bloch I, Regis J, Lopez-Krahe J. 1995. From 3D magnetic resonance images to structural representations of the cortex topography using topology preserving deformations. *J Math Imag Vis*. 5:297-318.
- Mangin JF, Riviere D, Cachia A, Duchesnay E, Cointepas Y, Papadopoulos-Orfanos D, Scifo P, Ochiai T, Brunelle F, Regis J. 2004. A framework to study the cortical folding patterns. *Neuroimage*. 23(1 Suppl):S129-S138.
- Munte TF, Altenmüller E, Jäncke L. 2002. The musician's brain as a model of neuroplasticity. *Nat Rev Neurosci*. 3:473-478.
- Pascual-Leone A, Cohen LG, Dang N, Brasil-Neto JP, Cammarota A, Hallett M. 1993. Acquisition of fine motor skills in humans is associated with the modulation of cortical motor output maps. *Neurology*. 43:157.
- Pascual-Leone A, Nguyet D, Cohen LG, Brasil-Neto JP, Cammarota A, Hallett M. 1995. Modulation of muscle responses evoked by transcranial magnetic stimulation during the acquisition of new fine motor skills. *J Neurophysiol*. 74:1037-1045.
- Penfield W, Rasmussen T. 1950. The cerebral cortex of the man. New York: Macmillan.
- Pizer SM, Fritsch DS, Yushkevich PA, Johnson VE, Chaney EL. 1999. Segmentation, registration and measurement of shape variation via image object shape. *IEEE Trans Med Imaging*. 18:851-865.
- Sastre-Janer FA, Regis J, Belin P, Mangin JF, Dormont D, Masure MC, Remy P, Frouin V, Samson Y. 1998. Three-dimensional reconstruction of the human central sulcus reveals a morphological correlate of the hand area. *Cereb Cortex*. 8:641-647.
- Schlaug G. 2001. The brain of musicians: a model for functional and structural adaptation. *Ann N Y Acad Sci*. 930:281-299.
- Schlaug G, Knorr U, Seitz R. 1994. Inter-subject variability of cerebral activations in acquiring a motor skill: a study with positron emission tomography. *Exp Brain Res*. 98:523-534.
- Schlaug G, Norton A, Overy K, Winner E. 2005. Effects of music training on the child's brain and cognitive development. *Ann N Y Acad Sci*. 1060:219-230.
- Styner M, Lieberman JA, Pantazis D, Gerig G. 2004. Boundary and medial shape analysis of the hippocampus in schizophrenia. *Med Image Anal*. 8:197-203.
- Talairach J, Tournoux P. 1988. Co-planar stereotaxic atlas of the human brain. New York: Thieme Medical Publishers.
- Thompson PM, Moussai J, Zohoori S, Goldkorn A, Khan AA, Mega MS, Small GW, Cummings JI, Toga AW. 1998. Cortical variability and



- asymmetry in normal aging and Alzheimer's disease. *Cereb Cortex*. 8:492-509.
- Thompson PM, Schwartz C, Lin RT, Khan AA, Toga AW. 1996. Three-dimensional statistical analysis of sulcal variability in the human brain. *J Neurosci*. 16:4261-4274.
- Watanabe D, Savion-Lemieux T, Penhune VB. 2007. The effect of early musical training on adult motor performance: evidence for a sensitive period in motor learning. *Exp Brain Res*. 176:332-340.
- White LE, Andrews TJ, Hulette C, Richards A, Groelle M, Paydarfar J, Purves D. 1997a. Structure of the human sensorimotor system. I: morphology and cytoarchitecture of the central sulcus. *Cereb Cortex*. 7:18-30.
- White LE, Andrews TJ, Hulette C, Richards A, Groelle M, Paydarfar J, Purves D. 1997b. Structure of the human sensorimotor system. II: lateral symmetry. *Cereb Cortex*. 7:31-47.
- Yousry TA, Schmid UD, Alkadhi H, Schmidt D, Peraud A, Buettner A, Winkler P. 1997. Localization of the motor hand area to a knob on the precentral gyrus. A new landmark. *Brain*. 120:141-157.
- Yushkevich P, Joshi S, Pizer SM, Csernansky JG, Wang LE. 2003. Feature selection for shape-based classification of biological objects. *IPMI Proc LNCS*. 2732:114-125.